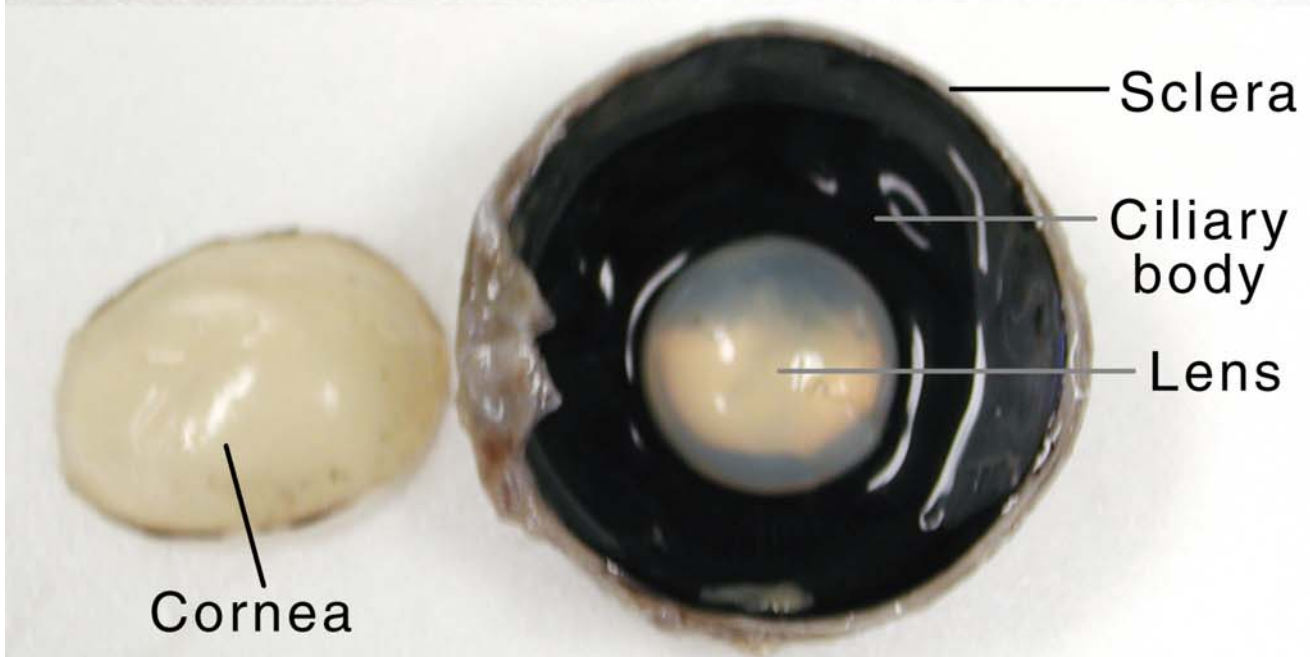




Front View of Anterior half of eye
(with cornea removed)



Back View of Anterior half of eye
(with cornea removed)